

Myelin Oligodendrocyte Glycoprotein (MOG) Antibody-Associated Optic Neuritis – A Case Report and Literature Review

Barbara Nowacka , Wojciech Lubiński , Beata Kaźmierczak

2nd Department of Ophthalmology, Pomeranian Medical University, Szczecin, Poland

Correspondence: Wojciech Lubiński, Email lubinski@pro.onet.pl

Background: Myelin oligodendrocyte glycoprotein (MOG)-IgG-associated optic neuritis (ON) is a new subset of demyelinating optic neuropathy.

Case Report: This study presents a case of a 49-year-old woman with MOG-IgG-positive ON, who reported to the ophthalmic emergency room with decreased visual acuity, retrobulbar pain and red color desaturation in her left eye. Abnormalities in the ophthalmological examination were: decreased Snellen's distance best-corrected visual acuity (DBCVA) to 0.04 in her left eye, slightly elevated optic nerve disc in the left eye confirmed by increased peripapillary retinal nerve fiber layer (RNFL) thickness in SD-OCT, abnormalities in pattern visual evoked potentials in both eyes. The preliminary diagnosis was demyelinating optic neuritis left for observation. However, two weeks after the first symptoms, treatment with intravenous methylprednisolone was initiated due to a decrease in DBCVA to no light perception. Intravenous steroids were followed by oral prednisone and later also by mycophenolate mofetil. The patient experienced slow but gradual improvement. One year after the occurrence of the initial symptoms, DBCVA was 0.5 in the left eye, however partial atrophy of the optic nerve developed, confirmed by macular ganglion cell layer (GCL) thickness and RNFL atrophy in SD-OCT, while visual pathway function improved.

Conclusion: All atypical cases of ON should be primarily considered for cell-based assays. MOG-IgG-positive ON usually responds well to steroid drugs and delaying immunosuppressive treatment may cause irreversible damage to the optic nerve.

Keywords: myelin oligodendrocyte glycoprotein, MOG, optic neuritis, multiple sclerosis, aquaporin 4, neuromyelitis optica spectrum disorder

Introduction

Optic neuritis (ON) is one of the main manifestations of inflammatory conditions in the central nervous system. It may be the first symptom of multiple sclerosis (MS) and neuromyelitis optica spectrum disorders (NMOSD). Among the latter, more than 80% of cases are caused by autoantibodies to aquaporin 4 (AQP4), the most frequent water channel protein in the central nervous system. Until recently, the rest was classified as AQP4-seronegative NMOSD. In 2007, the myelin oligodendrocyte glycoprotein immunoglobulin G (MOG-IgG) was discovered. However, widespread testing was not available until years later. Now even 42% of cases described prior as AQP4-seronegative NMOSD have been identified as myelin oligodendrocyte glycoprotein (MOG) antibody-associated disease (MOGAD).¹⁻⁴ Table 1 describes the characteristic features of optic neuritis associated with MOG-IgG, AQP4-IgG and MS. Apart from MS and NMOSD caused by AQP4-IgG, the differential diagnosis includes nonarteritic anterior optic neuropathy, sarcoidosis, Lyme disease and granulomatosis with polyangiitis (Wegener's granulomatosis).

Oligodendrocytes are a type of glial cells. They form a myelin sheath on optic nerve axons. Myelin oligodendrocyte glycoprotein is one of surface proteins that is found only in the central nervous system. Its most important function is the formation and maintenance of myelin sheaths.⁴ Autoantibodies to MOG can activate the classical pathway of the complement cascade and induce a cytotoxic reaction, leading to primary demyelinating damage, sparing axons and

Table 1 Characteristic Features of Optic Neuritis Associated with MOG-IgG, AQP4-IgG and Multiple Sclerosis (MS)

	MOG-IgG ON	AQP4-IgG ON	MS ON
Eye pain	Very frequent	Less frequent	Frequent
Bilateral	Frequent (72.7%)	Less frequent (24%)	Exceptionally
Severe visual loss at onset	Very frequent	Very frequent	Frequent
Optic disc edema	Frequent (86%), sometimes severe with haemorrhages	Rare	30%
Recurrence risk	Very frequent (50%)	Very frequent	Frequent
Severe visual loss risk	Infrequent	Very frequent	Infrequent
PVEP	↑ P100 peak time + normal or mildly ↓ amplitude	↑ P100 peak time + mildly ↓ amplitude, ↓ amplitude with normal latency, absent response	↑ P100 peak time + normal or mildly ↓ amplitude
Visual field	Central scotomas to complete visual loss	Total loss, central, quadrant, altitudinal	Diffuse field loss, central scotoma
OCT	Acute peripapillary RNFL and GCC thickening, followed by thinning, worsens with recurrence	Severe peripapillary RNFL thinning	Acute peripapillary RNFL and GCC thickening, followed by thinning
Optic nerve MRI	Enhancement of >50%, orbital portion involved (lesions extend from anterior portion to whole length), frequent perineural enhancement	Lesions often extend from posterior portion to whole length, frequent chiasm involvement	Short lesions, usually parenchymal optic nerve enhancement
Steroid treatment	i.v. steroids followed by p.o. prednisolone	Frequently resistant to steroid therapy	Fasten recovery but no influence on final visual acuity

Abbreviations: PVEP, pattern visual evoked potentials; OCT, optic coherence tomography; RNFL, retinal nerve fibre layer; GCC, ganglion cell complex; MRI, magnetic resonance imaging; i.v, intravenous; p.o, per os.

astrocytes in the initial stage of the disease,^{5,6} in contrast to AQP-4 antibodies which at first lead to massive destruction of astrocytes and disturbance of the blood-brain barrier function, then secondary damage to the myelin sheath.⁷ The gold standard in MOGAD suspected cases is serological diagnostics of MOG-IgG. The cerebrospinal fluid analysis is neither sensitive nor specific and usually show normal results or a pleocytosis with a range of white blood cell counts. Very few patients were found to have oligoclonal bands as seen in MS.^{8,9} This study presents a case report of a patient with MOG-IgG-positive ON and literature review. The patient gave informed consent for publication. The institutional approval was not required to publish the case details.

Case Report

A 49-year-old female reported to the clinical ophthalmic emergency room with complaints of decreased visual acuity, retrobulbar pain on eye movement and red color desaturation in her left eye. The ophthalmological examination revealed Snellen’s distance best-corrected visual acuity (DBCVA) of 1.0 in her right eye and 0.04 in her left eye, normal intraocular pressure in both eyes, left side relative afferent pupillary defect (RAPD), normal anterior segment of both eyes and normal fundus of the right eye. However, the optic disc was slightly elevated with marked borders in the left eye and optical coherence tomography (SD-OCT) confirmed increased peripapillary retinal nerve fiber layer thickness (RNFL) with a normal result for macular ganglion cell layer (GCL) thickness (Figure 1). Basic laboratory tests

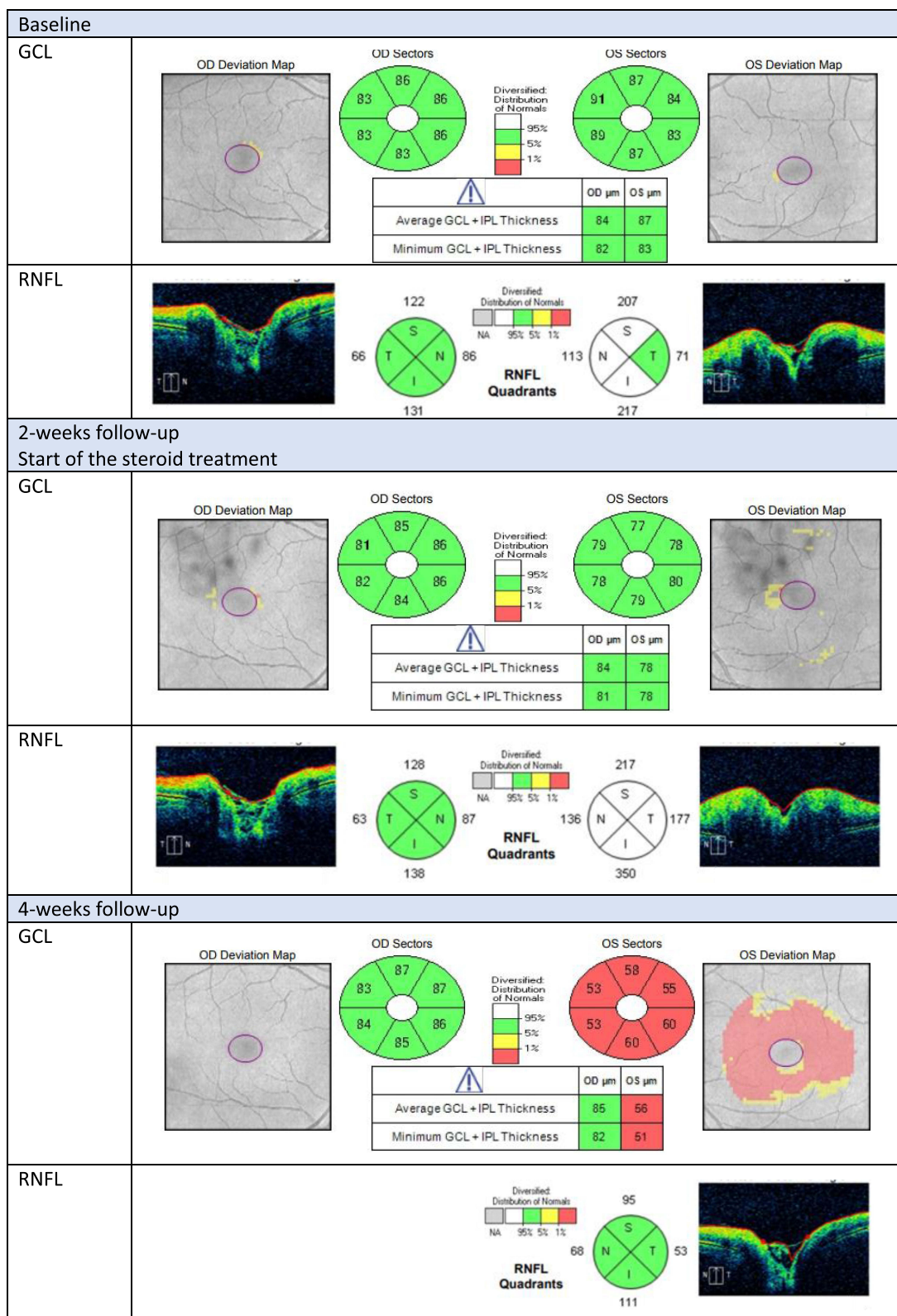


Figure 1 Continued.

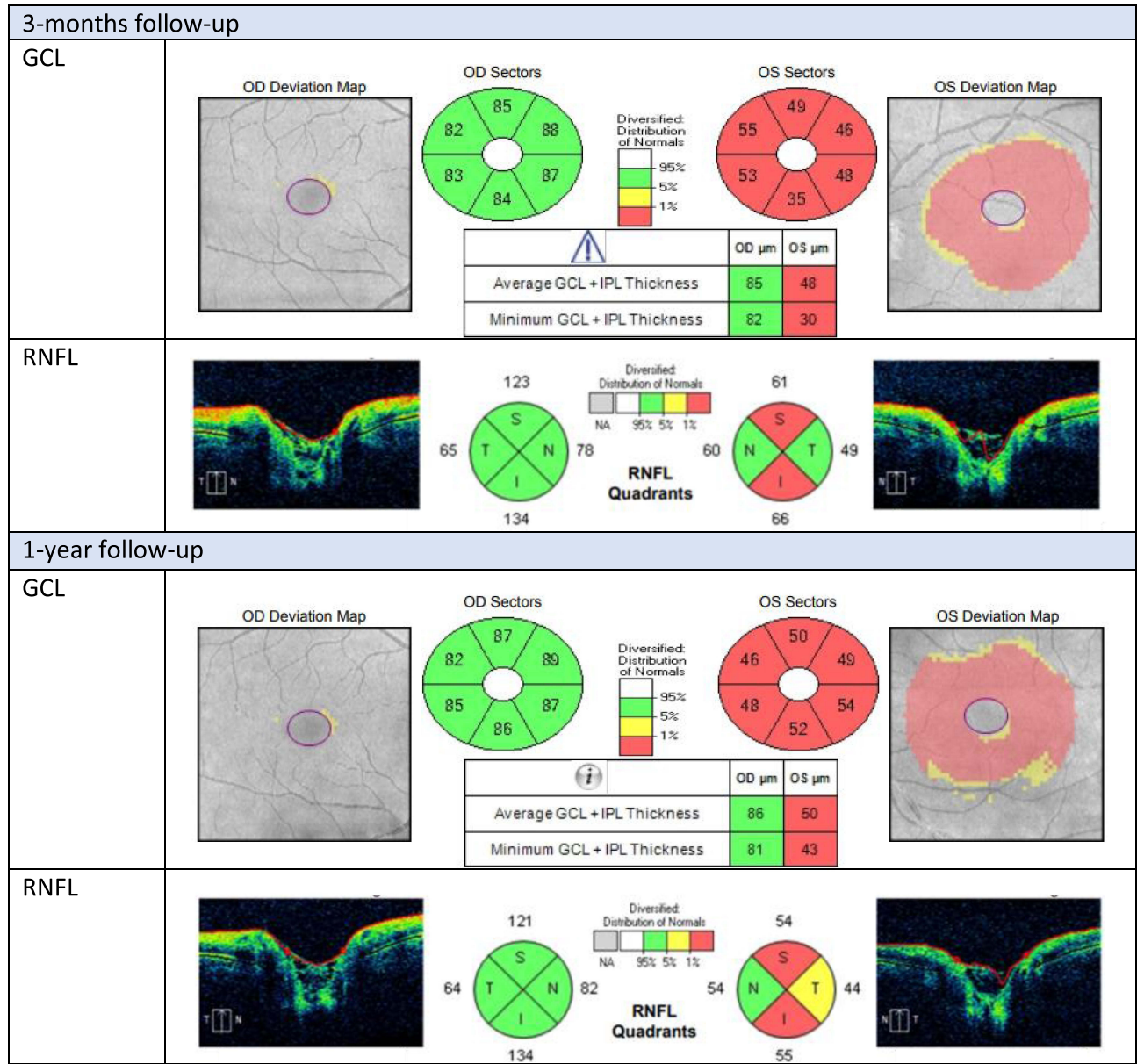


Figure 1 Evaluation of ganglion cell layer (GCL) and retinal nerve fiber layer (RNFL) in Optical Coherence Tomography (OCT) of a patient with myelin oligodendrocyte glycoprotein (MOG) antibody-associated optic neuritis during 1-year follow-up.

Abbreviations: GCL, ganglion cell layer; RNFL, retinal nerve fiber layer.

(sedimentation rate, c-reactive protein) were normal. Pattern visual evoked potentials (PVEPs, ISCEV Standard 2016 [4]) showed slightly increased latencies of P100 waves for a large ($1^{\circ} 4'$) checkerboard in both eyes and a reduction of P100 amplitude for a large ($1^{\circ} 4'$) and small ($0^{\circ} 16'$) checkerboards in the left eye (Figure 2). The patient was referred for scheduled head and orbit imaging. The preliminary diagnosis was demyelinating ON for observation, no treatment was initiated. However, after two weeks, the patient was admitted to the hospital due to a visual acuity decrease to no light perception in the left eye and exotropia. Ocular examination showed an increase in left optic nerve disc edema (Figure 3), confirmed by examination of RNFL in SD-OCT (Figure 1). The magnetic resonance imaging (MRI) showed inflammatory thickening of the left optic nerve throughout its entire thickness involving the left side of the optic chiasm. The right optic nerve and the right side of the optic chiasm were normal. There were no specific changes in the brain and spinal cord imaging. The serological indirect immunofluorescence revealed a positive result for MOG-IgG. Treatment of 1 g per day of intravenous methylprednisolone for 3 days was initiated, followed by oral prednisone (1 mg per kg bw

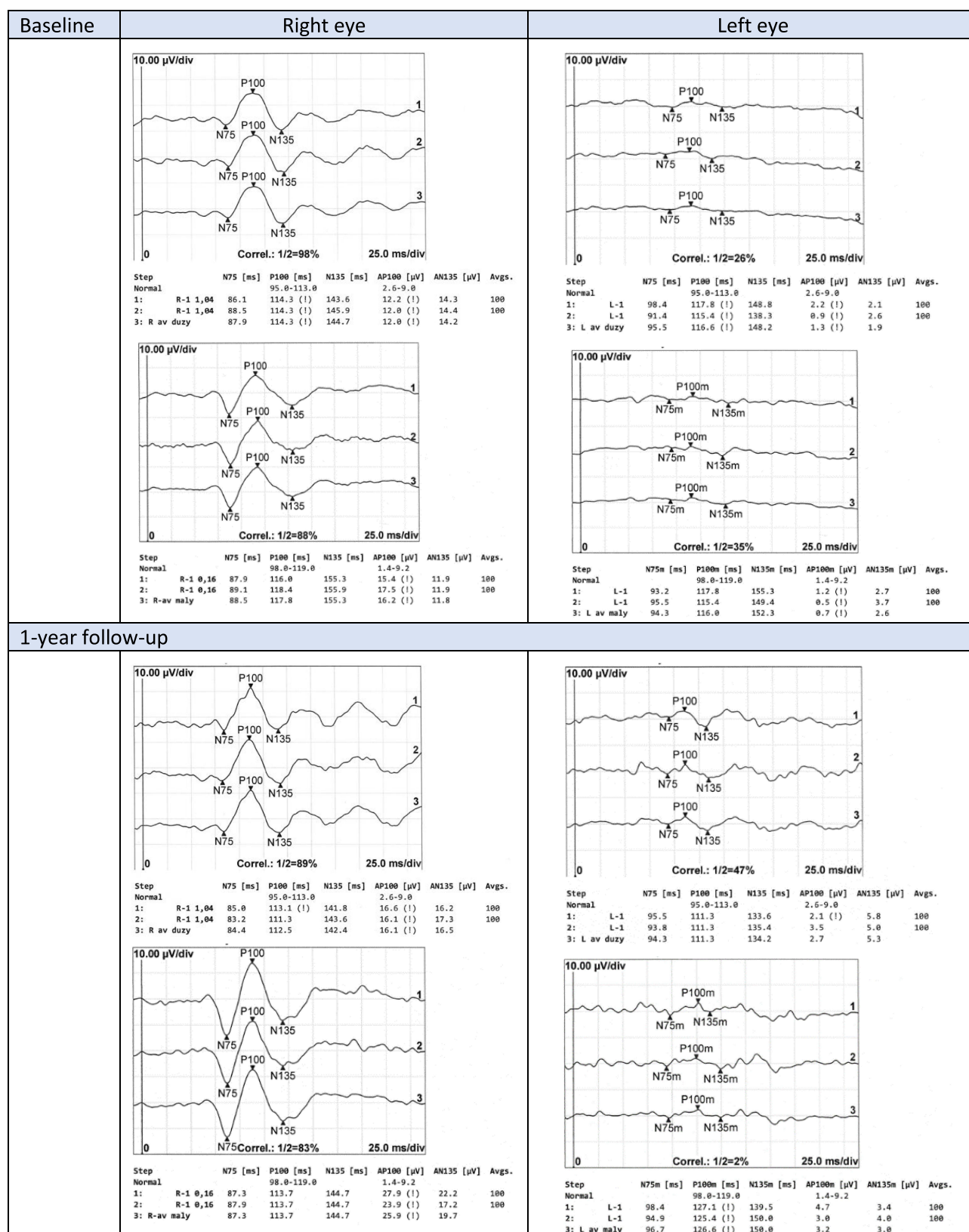


Figure 2 Evaluation of visual evoked potentials (PVEP) of a patient with myelin oligodendrocyte glycoprotein (MOG) antibody-associated optic neuritis in the left eye during 1-year follow-up.

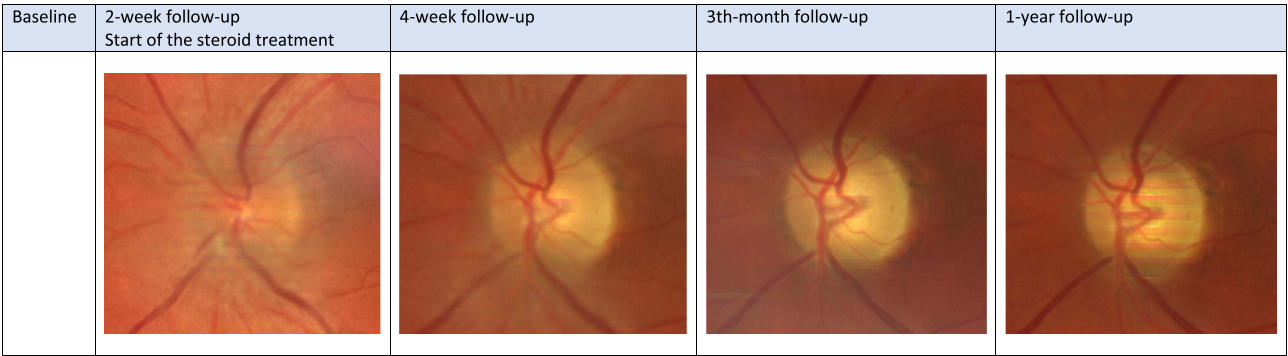


Figure 3 Evaluation of the optic nerve disc appearance of a patient with myelin oligodendrocyte glycoprotein (MOG) antibody-associated optic neuritis during 1-year follow-up.

initially, with a reduction of 5 mg per week). Two weeks after treatment began, DBCVA of the left eye improved to counting fingers at 30 centimeters and the reduction of the optic nerve edema was visible (Figure 3), however, the eye was still in exotropia. A further two weeks later, DBCVA was 0.02, the angle of the exotropia decreased, there was no visible disc edema (Figure 3) and RNFL was also within normal limits, but GCL reduction appeared (Figure 1). Kinetic perimetry performed at that time showed a narrowing of the visual field to central 10 degrees in the left eye (Figure 4).

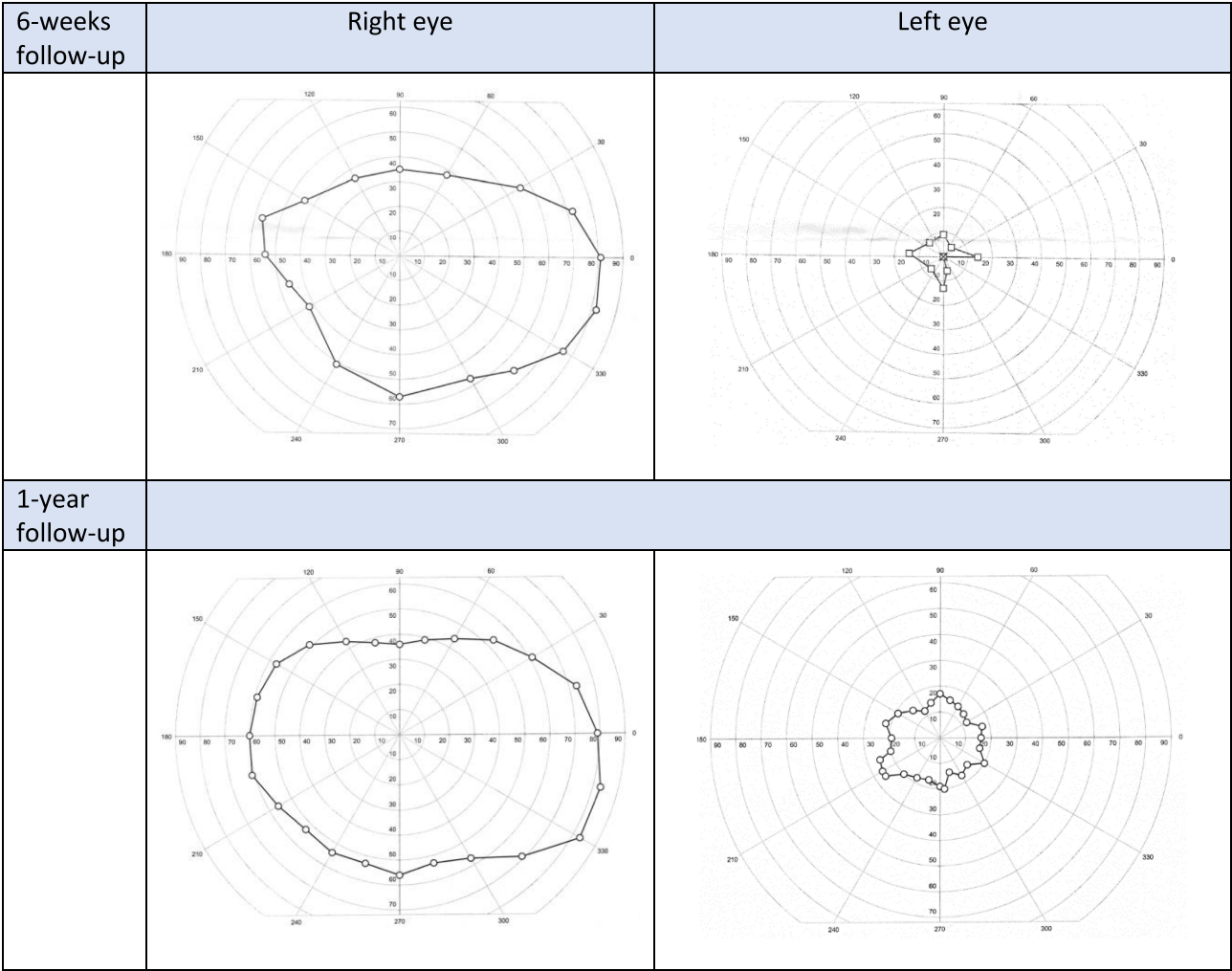


Figure 4 Evaluation of visual field of a patient with myelin oligodendrocyte glycoprotein (MOG) antibody-associated optic neuritis in the left eye during 1-year follow-up.

Three months after the beginning of the steroid treatment, DBCVA in the affected eye was 0.3 and only periodically did exotropia occur, no optic nerve disc edema was seen (Figure 3), however, a reduction of RNFL and GCL was observed in SD-OCT (Figure 1). To prevent the recurrence of ON, 20 mg of prednisone was planned to be maintained at least up to 6 months after the ON episode. However, the neurologist recommended maintaining treatment for up to one year and also added treatment with mycophenolate mofetil when the dose of 20 mg of prednisone was achieved. As there are currently no evidence-based guidelines for long-term follow-up in patients with MOGAD and some irreversible complications occurred in our case, treatment with mycophenolate mofetil will be continued till an undetermined point. At the examination of the patient's left eye one year after the ON episode, DBCVA was 0.5, exotropia occurred only in moments of lack of concentration, and optic nerve neuropathy was visible at the fundus of the eye (Figure 3), which was confirmed by RNFL and GCL reduction in SD-OCT (Figure 1). In the PVEPs, the only abnormality was a prolongation of P100 latency for a small ($0^{\circ} 16'$) checkerboard (Figure 2). The field of view has improved to 20 central degrees (Figure 4). All results from the patient's right eye were normal and no episode of ON was observed during the one-year follow-up.

Discussion

According to available literature, ON is the most common clinical presentation of MOGAD.⁸ Other described manifestations are acute disseminating encephalomyelitis (ADEM) and transverse myelitis (TM), isolated brainstem syndromes (eg eye movement disorder, hearing loss, trigeminal neuralgia, dysphagia, hemiparesis, dizziness, breathing problems) and less frequently encephalitis or seizures. At the onset, MOG-IgG-positive ON typically causes severe vision loss in the form of central scotomas to complete visual loss presented in up to 95% of patients.¹⁰ MOG-IgG-positive ON tends to be recurrent (in approximately 50% of patients) and bilateral (72.7% of MOG-IgG patients vs 24% of AQP4-IgG patients).^{8,11} In the acute phase, significant eye pain is common and it is also often associated with optic disc edema (in up to 86% of cases), which can sometimes be severe and include peripapillary hemorrhages.^{12–14} In the presented case, similarly, typical ON complaints and disc edema were observed, confirmed by RNFL elevation in SD-OCT in the left eye. Optical coherence tomography studies reported greater thickness of RNFL and GCL thickness in MOG-IgG-positive ON compared to AQP4-IgG-positive ON.^{15,16} Subsequently, optic nerve injury results in thinning of RNFL and GCC after the acute phase, whose severity is generally similar and more pronounced in NMOSD than in MS-related ON.^{17,18} However, despite a similar seriousness of RNFL and GCC thinning in MOG-IgG and AQP4-IgG-positive ON, visual outcomes are usually better in the first case.¹⁸ The authors have also observed increased peripapillary RNFL thickness but with a normal result for macular GCL thickness in the acute phase, followed by a progressive decrease of both parameters as optic nerve neuropathy developed. During the course of MOGAD-related ON, MRI of the optic nerve usually reveals longitudinal, usually over half of optic nerve length and anterior (the orbital and intracranial region of the optic nerve) enhancement, in opposition to AQP4-IgG-positive ON where the observed changes are more posterior, often with optic chiasm involvement. Another common MRI finding is optic perineuritis with optic nerve sheath enhancement in contrast to parenchymal optic nerve enhancement usually seen in MS-related ON.^{13,19} Brain MRI may reveal non-specific brainstem lesions adjacent surrounding the fourth ventricle, but their morphology is not as observed in MS (ovoid and adjacent to the lateral ventricles). The results of brain imaging may also be within normal limits. Magnetic resonance imaging of the spinal cord may reveal swelling and contrast enhancement that can resemble the transverse myelitis of NMOSD.⁸ In the presented case, MRI showed marked thickening of the left optic nerve throughout its entire thickness involving the left side of the optic chiasm with signs of inflammation, which is in opposition to typical anterior changes in MOG-IgG-positive ON. Perhaps extensive inflammation was a result of delayed imaging, because of a preliminary diagnosis of typical demyelinating ON, which was left for observation. There were no specific changes in brain and spinal cord imaging, which is consistent with the literature. As OCT and MRI give structural information about the optic nerve and retina, PVEPs provide information about the visual pathway function with particular emphasis on the optic nerve. Study results indicate that PVEPs at P100 latency are less delayed in NMOSD than MS, however absent responses are more frequent.²⁰ Prolongation of P100 latency often persists after the acute phase, even when visual acuity returns to normal.⁹ During the acute phase, the authors observed a reduction of P100 amplitude in the affected eye, while slight prolongation of P100 latency was observed in both eyes for a large ($1^{\circ} 4'$) checkerboard. However, as it is

described in the literature, more prominent changes were observed in P100 amplitude than latency, which was only slightly delayed. One year after the ON episode, the only electrophysiological abnormality was a prolongation of P100 latency for a small (0° 16') checkerboard from the left eye, while other parameters from the affected eye and results from the right eye were within normal limits. Randomized, controlled treatment trials are limited for MOGAD-related ON, but based on available results, it is recommended to use 1 g per day of intravenous methylprednisolone for 3–5 days for treatment of acute MOG-positive ON. Patients usually show rapid and significant improvement. Treatment with corticosteroids is almost always used to aid visual recovery, so data on the natural history without treatment are limited, but the recovery increase after intravenous steroids is rated at 10–20% compared to no treatment.¹⁹ A shorter time to treatment correlated with fewer RNFL losses and better visual outcomes.²¹ The optimal time of treatment initiation is within one week of the onset of symptoms (most preferably by day 4).²¹ In patients who do not respond to steroid treatment, intravenous immunoglobulin or plasma exchange can be used.^{8,19} There are no prospective trials to guide the maintenance therapy for MOG-positive ON, but observational open-label work suggests the role of oral steroids in preventing recurrent attacks. Notably, the majority of individuals in all studies had a recurrence within the first year from the onset of the disease,^{13,19} but the risk of relapse remains high within the next 5 years.^{12,22} Unfortunately, biomarkers that can predict ON relapses are lacking. Contentti et al reported tendency to monophasic clinical course in patients with higher MOG-IgG levels at the onset or those with rapidly disappearing antibodies after treatment during the acute phase.²³ In one study, 95% of patients receiving doses of at least 20 mg of prednisone for six months following an acute phase treatment had no recurrent ON episodes at follow-up of over a year.¹⁴ High doses and longer lengths of treatment were strongly associated with remittance, and patients who were given a tapered dose or discontinued therapy earlier had relapse rates comparable to those with no treatment.^{14,19} There are also data pointing to the role of immunosuppressive drugs, such as azathioprine, mycophenolate mofetil, interleukin-6 receptor inhibitor, rituximab and intravenous immunoglobulin, in reducing the relapse rate of MOGAD.^{14,19,24} In the case presented in this study, treatment of 1 g per day of intravenous methylprednisolone for 3 days was initiated two weeks after the presentation of symptoms. This may be a reason why the patient achieved only partial visual recovery, but also indicates that even delayed treatment has a role in maintaining useful visual acuity and preventing relapse. Treatment was continued with oral steroids at a dose of 1 mg per kg, with a reduction of 5 mg per week. When a dose of 20 mg of prednisone was achieved, the neurologist decided on initiation of treatment with mycophenolate mofetil. The use of immunosuppressive drugs in conjunction with low-dose oral steroids was observed to reduce the risk of relapses.¹³ During the one-year follow-up, we did not observe a recurrence of ON in the presented case, so it seems that this approach is effective.

Conclusions

The presented case confirms prior reports that MOG-IgG-associated ON responds well to steroid therapy and visual acuity outcomes are favorable. However, the treatment should be enrolled without delay to achieve the best results. That is why, all cases of ON with severe vision loss and optic nerve disc edema, bilateral ON or recurrent ON should be primarily considered for cell-based assays for detecting MOG-IgG. The risk of recurrence is high during the first year, and subsequent attacks are linked with an increased risk of permanent neurologic deficit, so prolonged immunosuppressive treatment seems to be mandatory. Further research is needed to determine the optimal long-term therapy for MOGAD.

Disclosure

The authors report no conflicts of interest in this work.

References

1. Hamid SHM, Whittam D, Mutch K. et al. What proportion of AQP4-IgG-negative NMO spectrum disorder patients are MOG-IgG positive? A cross sectional study of 132 patients. *J Neurol*. 2017;264(10):2088–2094. doi:10.1007/s00415-017-8596-7
2. Hyun JW, Woodhall MR, Kim SH, et al. Longitudinal analysis of myelin oligodendrocyte glycoprotein antibodies in CNS inflammatory diseases. *J Neurol Neurosurg Psychiatry*. 2017;88(10):811–817. doi:10.1136/jnnp-2017-315998

3. Jarius S, Ruprecht K, Kleiter I, et al.; in cooperation with the Neuromyelitis Optica Study Group (NEMOS). MOG-IgG in NMO and related disorders: a multicenter study of 50 patients. Part 1: frequency, syndrome specificity, influence of disease activity, long-term course, association with AQP4-IgG, and origin. *J Neuroinflammation*. 2016;13(1):279. doi:10.1186/s12974-016-0717-1
4. Narayan R, Simpson A, Fritsche K, et al. MOG antibody disease: a review of MOG antibody seropositive neuromyelitis optica spectrum disorder. *Mult Scler Relat Disord*. 2018;25:66–72. doi:10.1016/j.msard.2018.07.025
5. Mader S, Gredler V, Schanda K, et al. Complement activating antibodies to myelin oligodendrocyte glycoprotein in neuromyelitis optica and related disorders. *J Neuroinflammation*. 2011;8:184.
6. Brilot F, Dale RC, Selter RC, et al. Antibodies to native myelin oligodendrocyte glycoprotein in children with inflammatory demyelinating central nervous system disease. *Ann Neurol*. 2009;66(6):833–842. doi:10.1002/ana.21916
7. de Mol CL, Wong Y, van Pelt ED, et al. The clinical spectrum and incidence of anti-MOG-associated acquired demyelinating syndromes in children and adults. *Mult Scler*. 2020;26(7):806–814. doi:10.1177/1352458519845112
8. Tajfirouz DA, Bhatti MT, Chen JJ. Clinical Characteristics and Treatment of MOG-IgG-Associated Optic Neuritis. *Curr Neurol Neurosci Rep*. 2019;19(12):100. doi:10.1007/s11910-019-1014-z
9. Jurynczyk M, Gheraldes R, Probert F, et al. Distinct brain imaging characteristics of autoantibody-mediated CNS conditions and multiple sclerosis. *Brain*. 2017;140(3):617–627. doi:10.1093/brain/aww350
10. Zhao Y, Tan S, Chan TCY, et al. Clinical features of demyelinating optic neuritis with seropositive myelin oligodendrocyte glycoprotein antibody in Chinese patients. *Br J Ophthalmol*. 2018;102(10):1372–1377. doi:10.1136/bjophthalmol-2017-311177
11. Jarius S, Paul F, Aktas O, et al. MOG encephalomyelitis: international recommendations on diagnosis and antibody testing. *J Neuroinflammation*. 2018;15(1):134. doi:10.1186/s12974-018-1144-2
12. Chen JJ, Flanagan EP, Jitrapaikulsan J, et al. Myelin oligodendrocyte glycoprotein antibody-positive optic neuritis: clinical characteristics, radiologic clues, and outcome. *Am J Ophthalmol*. 2018;195:8–15. doi:10.1016/j.ajo.2018.07.020
13. Ramanathan S, Mohammad S, Tantis E, et al.; Australasian and New Zealand MOG Study Group. Clinical course, therapeutic responses and outcomes in relapsing MOG antibody-associated demyelination. *J Neurol Neurosurg Psychiatry*. 2018;89(2):127–137. doi:10.1136/jnnp-2017-316880
14. Jarius S, Ruprecht K, Kleiter I, et al.; in cooperation with the Neuromyelitis Optica Study Group (NEMOS). MOG-IgG in NMO and related disorders: a multicenter study of 50 patients. Part 2: epidemiology, clinical presentation, radiological and laboratory features, treatment responses, and long-term outcome. *J Neuroinflammation*. 2016;13(1):280. doi:10.1186/s12974-016-0718-0
15. Martinez-Lapiscina EH, Sepulveda M, Torres-Torres R, et al. Usefulness of optical coherence tomography to distinguish optic neuritis associated with AQP4 or MOG in neuromyelitis optica spectrum disorders. *Ther Adv Neurol Disord*. 2016;9(5):436–440. doi:10.1177/1756285616655264
16. Toosy AT, Mason DF, Miller DH. Optic neuritis. *Lancet Neurol*. 2014;13(1):83–99. doi:10.1016/S1474-4422(13)70259-X
17. Sotirchos ES, Filippatou A, Fitzgerald KC, et al. Aquaporin-4 IgG seropositivity is associated with worse visual outcomes after optic neuritis than MOG-IgG seropositivity and multiple sclerosis, independent of macular ganglion cell layer thinning. *Mult Scler*. 2020;26(11):1360–1371. doi:10.1177/1352458519864928
18. Neto S, Alvarenga R, Vasconcelos C, et al. Evaluation of pattern-reversal visual evoked potential in patients with neuromyelitis optica. *Mult Scler*. 2013;19(2):173–178. doi:10.1177/1352458512447597
19. Ishikawa H, Kezuka T, Shikishima K, et al. Working group on diagnostic criteria for refractory optic neuritis based on neuroimmunological perspective. epidemiologic and clinical characteristics of optic neuritis in Japan. *Ophthalmology*. 2019;126(10):1385–1398. doi:10.1016/j.ophtha.2019.04.042
20. Takano S, Hanabusa A, Yoshikawa Y, et al. Pattern visually evoked potentials in Japanese girl with optic neuritis and seropositive to Anti-myelin Oligodendrocyte Glycoprotein (MOG) Antibody. *Front Neurol*. 2019;10:1339. doi:10.3389/fneur.2019.01339
21. Stiebel-Kalish H, Hellmann MA, Mimouni M, et al. Does time equal vision in the acute treatment of a cohort of AQP4 and MOG optic neuritis? *Neurol Neuroimmunol Neuroinflamm*. 2019;6:e572.
22. Cobo-Calvo A, Sepúlveda M, Rollot F, et al. Evaluation of treatment response in adults with relapsing MOG-Ab-associated disease. *J Neuroinflammation*. 2019;16(1):134. doi:10.1186/s12974-019-1525-1
23. Carnero Contentti E, Marroden M, Correale J. Emerging drugs for the treatment of adult MOG-IgG-associated diseases. *Expert Opin Emerg Drugs*. 2021;26(2):75–78. doi:10.1080/14728214.2021.1919082
24. Elsbernd PM, Hoffman WR, Carter JL, Wingerchuk DM. Interleukin-6 inhibition with tocilizumab for relapsing MOG-IgG associated disorder (MOGAD): a case-series and review. *Mult Scler Relat Disord*. 2021;48:102696. doi:10.1016/j.msard.2020.102696

International Medical Case Reports Journal

Dovepress

Publish your work in this journal

The International Medical Case Reports Journal is an international, peer-reviewed open-access journal publishing original case reports from all medical specialties. Previously unpublished medical posters are also accepted relating to any area of clinical or preclinical science. Submissions should not normally exceed 2,000 words or 4 published pages including figures, diagrams and references. The manuscript management system is completely online and includes a very quick and fair peer-review system, which is all easy to use. Visit <http://www.dovepress.com/testimonials.php> to read real quotes from published authors.

Submit your manuscript here: <https://www.dovepress.com/international-medical-case-reports-journal-journal>