



# Straight Back Syndrome Presented with Chest and Back Pain: A Case Report

Hiroshi Shiba <sup>1</sup>, Tsuneaki Kenzaka <sup>2,3</sup>

<sup>1</sup>Department of Internal Medicine, Suwa Central Hospital, Chino, Japan; <sup>2</sup>Department of Internal Medicine, Hyogo Prefectural Tamba Medical Center, Tamba, Japan; <sup>3</sup>Division of Community Medicine and Career Development, Kobe University Graduate School of Medicine, Kobe, Japan

Correspondence: Hiroshi Shiba, Department of Internal Medicine, Suwa Central Hospital, 4300 Tamagawa, Chino, Nagano-ken, 391-8503, Japan, Tel +81-0266-72-1000, Fax +81-0266-72-4120, Email hshiba0124@gmail.com

**Abstract:** A 17-year-old female adolescent presented with her mother to our clinic with a two-month history of left-sided chest pain and a one-week history of middle back pain. We diagnosed straight back syndrome based on the chest and thoracic radiographic findings and symptoms of chest pain, palpitations, and dyspnea. We reassured the patient that the disease was benign and advised her to start and continue chiropractic therapy. All symptoms, including back pain, disappeared in three weeks. Straight back syndrome is under-diagnosed, and back pain is less recognized as a symptom of the disease.

**Keywords:** straight back syndrome, middle back pain, chest pain, palpitations, dyspnea

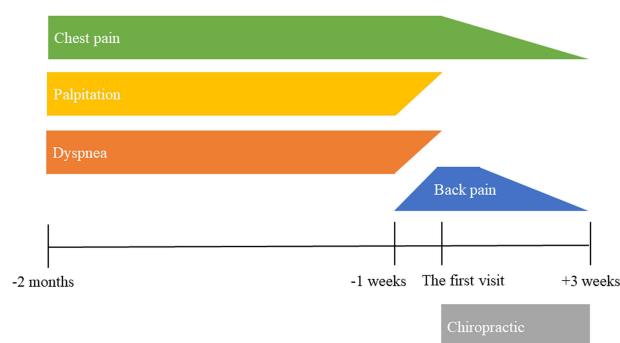
## Background

Straight back syndrome is a congenital disease first described by Rawlings in 1960.<sup>1,2</sup> It typically occurs in young, thin individuals who have a reduced sagittal diameter of the thoracic cage because of the absence of a normal thoracic kyphosis in the mid-upper dorsal spine.<sup>3</sup> It was considered to not be a rare condition.<sup>4</sup> In a case series of 50 patients, 36 were male patients with a mean age of 28 years (range 15–72 years), mean height of 1.71 m (range 1.45–1.89 m), and mean weight of 69.9 kg (range 49.3–111.5 kg). All patients had straightening of the upper dorsal spine, and two patients had mild pectus excavatum.<sup>5</sup> However, its incidence is still unknown partially due to under-diagnosis.<sup>6</sup> A diagnosis is made by the confirmation of straightened dorsal spine using chest radiography. DeLeon et al<sup>7</sup> first proposed the criterion, and Davies et al<sup>8</sup> modified it. Other findings on chest radiography include “pancake” appearance, simulated cardiomegaly, levoposition of the heart, and prominence of the main pulmonary artery.<sup>8</sup> Thoracic computed tomography is also used in diagnosis.<sup>9,10</sup>

Straight back syndrome is benign and usually asymptomatic; however, it may sometimes cause cardiovascular manifestations, mimicking organic heart disease.<sup>7</sup> Symptoms are considered to be caused by compression of the heart and great vessels.<sup>11</sup> Straight back syndrome may present with “cardiac” symptoms, such as palpitations, chest pain, and dyspnea.<sup>8</sup> We present a case of straight back syndrome with intermittent middle back pain because, to the best of our knowledge, this symptom has rarely been reported in the literature.

## Case Presentation

A 17-year-old female adolescent presented to our clinic with a two-month history of left-sided chest pain and a one-week history of left-sided back pain at the level of T7. The chest pain was accompanied by palpitations and dyspnea occurring 3 to 4 days per week. A week before the first visit, the palpitations and dyspnea became less frequent, and she developed a daily intermittent dull pain on the left side of the chest and middle back without radiation, simultaneously in most cases. The clinical course is shown in Figure 1. The pain occurred both on exertion and at rest, lasting for hours, with no alleviative or aggravating factors. She reported pain intensity of 2 to 6 on a 10-point scale. The intensity changed during an attack, and the average was 4. She was healthy otherwise. There was no limitation in daily life. She visited a local doctor one month prior to visiting our clinic. Holter electrocardiographic and laboratory test findings were normal. Her medical history included migraine for three



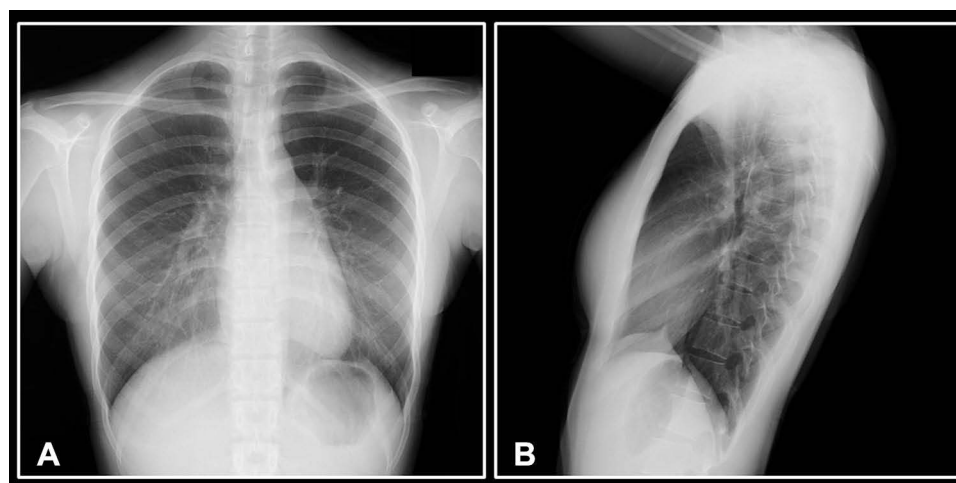
**Figure 1** Clinical course.

years. Her regular medications were lomerizine, loxoprofen, and naratriptan for the prevention and acute treatment of migraine. Her migraine was well controlled, and she rarely experienced attacks. She denied trauma or prior surgeries. She denied suspected symptoms or family history for autoimmune or inflammatory conditions.

Her blood pressure was 107/60 mmHg and pulse rate was 62 beats/min. She was 162 cm in height and 43 kg in weight, with a body mass index of 16.4 kg/m<sup>2</sup>. No murmur or arrhythmia was audible on her cardiovascular examination. The lungs were clear to auscultation bilaterally. Chest palpation provoked non-reproducible local pain in the lower sternocostal joints; horizontal arm traction maneuver and the crowing rooster maneuver provoked no pain. There was no tenderness on muscles and bones in the upper body.

Electrocardiographic and laboratory findings, including thyroid function, were normal. Chest and thoracic radiographic examination showed straightening of the upper thoracic spine and a loss of normal kyphotic curvature (Figure 2). Lower rib radiographs revealed no fracture or pneumothorax. We suspected straight back syndrome, according to the two different diagnostic criteria proposed by Davies et al<sup>8</sup> and DeLeon et al<sup>7</sup> (Table 1). The distance between the middle of the anterior border of T8 to a vertical line connecting T4 to T12 was 0.91 cm. The anteroposterior diameter was 74.0 cm, and the transverse diameter was 243.2 cm. We advised her to start and continue chiropractic therapy to increase thoracic kyphosis. We proceeded with watchful waiting for one month in outpatient care.

After this first visit, the chest and back pain gradually relieved. Palpitations and dyspnea scarcely occurred. All symptoms disappeared within three weeks. At the one-month follow-up visit, echocardiography was performed, revealing trivial mitral regurgitation without prolapse. We confirmed the diagnosis of straight back syndrome. We reassured the patient that the disease is benign, and advised her to continue chiropractic therapy. She has not had relapse of severe symptoms or the need to visit the hospital. She never visited our clinic in the subsequent year.



**Figure 2** Chest radiographs.

**Notes:** (A) Anteroposterior view demonstrates clear lung fields. (B) Lateral view demonstrates a straight thoracic spine and a narrow anteroposterior diameter.

**Table I** Diagnostic Criteria for Straight Back Syndrome

Study	Criteria
Davies et al <sup>8</sup>	The distance between the middle of the anterior border of T8 to a vertical line connecting T4 to T12 < 1.2 cm.
DeLeon et al <sup>7</sup>	A ratio of the anteroposterior to the transverse diameter was or less than 1:3.

## Discussion

We have presented a case of straight back syndrome with intermittent middle back pain. During the course of the disease, the back pain disappeared together with the chest pain. We diagnosed straight back syndrome based on the radiographic findings and the symptoms of chest pain, palpitations, and dyspnea. Frequent concomitant symptoms that have been reported include palpitations (38%), chest pain (29%), and dyspnea (19%).<sup>8</sup> Although back pain can be a primary symptom, its frequency remains unknown.<sup>12–14</sup> In our case, the three typical symptoms were accompanied by middle back pain. In our opinion, we can attribute the back pain to straight back syndrome based on the convergence projection theory. The pathophysiology of straight back syndrome is yet to be clarified; however, chest symptoms can be explained by compression of the heart and great vessels.<sup>11</sup> In rare cases, straight back syndrome induced pathological Q wave on electrocardiography with normal serum cardiac biomarkers, and even myocardial damage manifesting as acute myocardial infarction.<sup>15,16</sup> Patients with acute coronary syndromes sometimes present with referred pain in the back or jaw.<sup>17</sup> This can be explained by the convergence projection theory, in that the convergence of visceral and somatic stimuli can lead to referred somatic pain.<sup>17</sup> Women are more likely than men to have pain radiating to the back in myocardial infarction (34.2% vs 17.4%).<sup>18</sup> We cannot state that our patient suffered from acute myocardial infarction; however, it is physiologically reasonable that straight back syndrome can cause middle back pain as well as chest pain. As the back pain mostly occurred simultaneously with chest pain regardless of physical movement, it is less likely to be caused by muscles or joints.

The early diagnosis of straight back syndrome may lead to early detection and proper management of valvular heart disease. The presentation of straight back syndrome can vary from asymptomatic to a wide range of symptoms associated with various abnormal cardiac findings.<sup>19</sup> This may be a cause of its under-diagnosis. The diagnosis of straight back syndrome is usually based on clinical symptoms and chest radiography; however, echocardiography is recommended to evaluate organic heart diseases.<sup>5</sup> It is because straight back syndrome is often associated with valvular heart disease, especially mitral valve prolapse. Davies et al<sup>8</sup> found that 67% of patients had clinical or echocardiographic evidence of mitral valve prolapse. Ansari et al<sup>5</sup> reported that 58% of patients had echocardiographic evidence of mitral valve prolapse. In our case, an echocardiogram revealed trivial mitral regurgitation, but not mitral valve prolapse. It did not explain the chest symptoms and required no further intervention.

Treatments include watchful waiting, conservative treatment, and surgery. The disease is typically benign in nature even with subjective symptoms.<sup>3</sup> Recent reports have shown that chiropractic therapy to improve thoracic kyphosis may be effective.<sup>12–14</sup> Some patients with severe airway compression require operative treatment.<sup>20</sup> We found that this patient's condition was not severe to undergo surgery, and we advised her to perform active pectoralis muscle stretch involving shoulder extension with scapular retraction. The patient's symptoms disappeared by this chiropractic therapy.

## Conclusions

We have presented a case of straight back syndrome with middle back pain. Straight back syndrome may occur more frequently and may be overlooked due to the misdiagnosis. Highlighting the condition will provide healthcare professionals more knowledge on identification and management of the condition. In patients with middle back pain accompanied by chest symptoms, we suggest considering the possibility of straight back syndrome.

## Data Sharing Statement

All data generated or analyzed during this study are included in this published article.

## Ethics Approval and Consent for Publication

The ethics approval is not applicable. Written consent was obtained from the patient and the patient's mother for the publication of this case report and accompanying images.

## Funding

This research did not receive any specific grant from funding agencies in the public, commercial, or not-for-profit sectors.

## Disclosure

The authors declare that they have no competing interests.

## References

1. Rawlings MS. The "straight back" syndrome, a new cause of pseudoheart disease. *Am J Cardiol.* 1960;5(3):333–338. doi:10.1016/0002-9149(60)90080-1
2. Rawlings MS. Straight back syndrome: a new heart disease. *Dis Chest.* 1961;39(4):435–443. doi:10.1378/chest.39.4.435
3. Esser SM, Monroe MH, Littmann L. Straight back syndrome. *Eur Heart J.* 2009;30(14):1752. doi:10.1093/eurheartj/ehp197
4. Datey KK, Deshmukh MM, Engineer SD, Dalvi CP. Straight back syndrome. *Br Heart J.* 1964;26(5):614–619. doi:10.1136/hrt.26.5.614
5. Ansari A. The "straight back" syndrome: current perspective more often associated with valvular heart disease than pseudoheart disease: a prospective clinical, electrocardiographic, roentgenographic, and echocardiographic study of 50 patients. *Clin Cardiol.* 1985;8(5):290–305. doi:10.1002/clc.4960080509
6. Gold PM, Albright B, Anani S, Toner H. Straight back syndrome: positive response to spinal manipulation and adjunctive therapy – a case report. *J Can Chiropr Assoc.* 2013;57(2):143–149.
7. Deleon AC, Perloff JK, Twigg H, Majd M. The straight back syndrome: clinical cardiovascular manifestations. *Circulation.* 1965;32:193–203. doi:10.1161/01.CIR.32.2.193
8. Davies MK, Mackintosh P, Cayton RM, Page AJF, Shiu MF, Littler WA. The straight back syndrome. *Q J Med.* 1980;49(196):443–460.
9. Raggi P, Callister TQ, Lippolis NJ, Russo DJ. Is mitral valve prolapse due to cardiac entrapment in the chest cavity? A CT view. *Chest.* 2000;117(3):636–642. doi:10.1378/chest.117.3.636
10. Tokushima T, Utsunomiya T, Ogawa T, et al. Contrast-enhanced radiographic computed tomographic findings in patients with straight back syndrome. *Am J Card Imaging.* 1996;10(4):228–234.
11. Kambe M. Straight back syndrome and respiratory failure. *JMAJ.* 2006;49(4):176–179.
12. Mitchell JR, Oakley PA, Harrison DE. Nonsurgical correction of straight back syndrome (thoracic hypokyphosis), increased lung capacity and resolution of exertional dyspnea by thoracic hyperkyphosis mirror image<sup>®</sup> traction: a CBP<sup>®</sup> case report. *J Phys Ther Sci.* 2017;29(11):2058–2061. doi:10.1589/jpts.29.2058
13. Betz JW, Oakley PA, Harrison DE. Relief of exertional dyspnea and spinal pains by increasing the thoracic kyphosis in straight back syndrome (thoracic hypo-kyphosis) using CBP<sup>®</sup> methods: a case report with long-term follow-up. *J Phys Ther Sci.* 2018;30(1):185–189. doi:10.1589/jpts.30.185
14. Fortner MO, Oakley PA, Harrison DE. Chiropractic biophysics management of straight back syndrome and exertional dyspnea: a case report with follow-up. *J Contemp Chiropr.* 2019;2(1):115–122.
15. Wang JY, Chen H, Su X. Straight back syndrome manifesting as acute myocardial infarction. *Am J Emerg Med.* 2016;34(9):1913.e1–e3. doi:10.1016/j.ajem.2016.02.022
16. Pei YH, Chen J, Gong JB, Liu TS. Straight back syndrome with pathological Q wave misdiagnosed as established myocardial infarction. *Br J Hosp Med.* 2016;77(5):306–307. doi:10.12968/hmed.2016.77.5.306
17. Foreman RD, Garrett KM, Blair RW. Mechanisms of cardiac pain. *Compr Physiol.* 2015;5(2):929–960.
18. Albarran J, Durham B, Gowers J, Dwight J, Chappell G. Is the radiation of chest pain a useful indicator of myocardial infarction? A prospective study of 541 patients. *Accid Emerg Nurs.* 2002;10(1):2–9. doi:10.1054/aaen.2001.0304
19. Soleti P, Wilson B, Vijayakumar AR, Chakravarthi PIS, Reddy CG. An interesting case of straight back syndrome and review of the literature. *Asian Cardiovasc Thorac Ann.* 2016;24(1):63–65. doi:10.1177/0218492314539335
20. Grillo HC, Wright CD, Darteville PG, Wain JC, Murakami S. Tracheal compression caused by straight back syndrome, chest wall deformity, and anterior spinal displacement: techniques for relief. *Ann Thorac Surg.* 2005;80(6):2057–2062. doi:10.1016/j.athoracsur.2005.05.026

International Medical Case Reports Journal

Dovepress

Publish your work in this journal

The International Medical Case Reports Journal is an international, peer-reviewed open-access journal publishing original case reports from all medical specialties. Previously unpublished medical posters are also accepted relating to any area of clinical or preclinical science. Submissions should not normally exceed 2,000 words or 4 published pages including figures, diagrams and references. The manuscript management system is completely online and includes a very quick and fair peer-review system, which is all easy to use. Visit <http://www.dovepress.com/testimonials.php> to read real quotes from published authors.

Submit your manuscript here: <https://www.dovepress.com/international-medical-case-reports-journal-journal>