

“Pronation Compensation Sign” as a New Diagnostic Tool for Carpal Tunnel Syndrome: A Prospective Preliminary Study

Jean Paul Brutus¹, Thiên-Trang Vo¹, Min Cheol Chang²

¹Exception MD, Montreal, Canada; ²Department of Rehabilitation Medicine, College of Medicine, Yeungnam University, Daegu, Republic of Korea

Correspondence: Min Cheol Chang, Department of Physical Medicine and Rehabilitation, College of Medicine, Yeungnam University, 317-1 Daemyungdong, Namku, Daegu, 705-717, Republic of Korea, Tel +82-53-620-4862, Email wheel633@gmail.com

Purpose: Carpal tunnel syndrome (CTS) is commonly encountered in clinical practice. Diagnostic tools that currently exist include painful provocative maneuvers, invasive nerve conduction studies and the use of tests that require physician’s direct participation in an era of sanitary crisis and virtual consultations. Therefore, having an easily accessible, reliable and practical tool for diagnosing CTS would be highly beneficial. Herein, we investigated the diagnostic value of the “pronation compensation sign” that we described for diagnosing CTS.

Patients and Methods: We included 18 hands with and 18 hands without CTS (age: CTS hands = 52.5 ± 13.8 years, non-CTS hands = 43.2 ± 12.3 years; sex ratio: CTS hands = 12:8, non-CTS hands = 9:9). The presence of the “pronation compensation sign” was evaluated in each included hand. The presence of the “pronation compensation sign” were compared between CTS and non-CTS hands using the chi-squared test. Statistical significance was set at $p < 0.05$. The sensitivity, specificity, positive predictive value (PPV), and negative predictive value (NPV) were calculated of the “pronation compensation sign” for CTS.

Results: All 18 hands with CTS showed a positive “pronation compensation sign”, while those without CTS were negative. All 18 hands that were positive for the “pronation compensation sign” were hands with CTS, while those that were negative were hands without CTS. The sensitivity and specificity of the “pronation compensation sign” for diagnosing CTS were both 100%. The PPV and NPV of the “pronation compensation sign” for CTS were both 1.000. The rates of the presence of the “pronation compensation sign” were significantly different between hands with and without CTS ($p < 0.001$).

Conclusion: The “pronation compensation sign” seems a useful tool for diagnosing CTS. We believe that the “pronation compensation sign” will help clinicians diagnose CTS with high diagnostic accuracy.

Keywords: carpal tunnel syndrome, pronation compensation sign, diagnosis, accuracy, hand

Introduction

Carpal tunnel syndrome (CTS) is a prevalent condition characterized by the compression of the median nerve as it passes through the carpal tunnel of the wrist.¹ CTS is a common disorder that impacts hand function and causes neuropathic pain. It affects 4–5% of people worldwide.² An early and accurate diagnosis of CTS is essential for appropriate management and timely intervention to prevent long-term complications.³

The diagnosis of CTS is based on a combination of clinical history, physical examination findings, and confirmatory nerve conduction study findings.⁴ Clinicians should examine the distribution of sensory symptoms and assess for a positive Phalen’s test, a positive Durkan’s test, and Tinel’s sign over the carpal tunnel area. The scratch collapse test and its confirmation with a cold spray test are useful for confirming entrapment site location.⁵ However, to perform an accurate physical examination, a sufficient level of experience in diagnosing neurological diseases is required.⁶ In addition, nerve conduction studies can only be performed by physicians specialized in the relevant medical field. As CTS is a frequently encountered condition, having an easily accessible and reliable diagnostic method, even for non-specialists in neurological diseases, would be highly beneficial.

Abductor pollicis brevis (APB) muscle weakness is common in patients with CTS but seldom assessed in clinical practice.⁷ Having noticed that weakness of this muscle can lead to wrist pronation to compensate for limited thumb abduction, here we investigated the “pronation compensation sign” as an additional diagnostic tool to demonstrate this weakness and diagnose CTS. The APB originates from the scaphoid, trapezium, and flexor retinaculum bones and inserts on the lateral aspect of the proximal phalanx and the metacarpophalangeal joint of the thumb.⁸ Innervated by the median nerve, it brings the thumb in palmar abduction anteriorly and perpendicularly to the plane of the palm and assists with thumb opposition and extension.⁸ When the median nerve becomes compressed distally in the carpal tunnel, varying degrees of weakness occur in the APB, with or without severe muscle atrophy, making palmar abduction of the thumb difficult. Patients with APB muscle weakness tend to compensate for this difficulty by pronating the wrist. The observation of this compensatory strategy led us to describe the “pronation compensation sign” and assess its utility as an additional diagnostic indicator for CTS.

In the current study, we investigated the diagnostic value of the “pronation compensation sign” for diagnosing CTS.

Materials and Methods

Patients

This prospective study included consecutive patients who visited a local hand clinic for neuropathic pain between May and July, 2023. This study received approval from the Institutional Review Board of Exception MD. All participants were fully informed about the study and informed consent was obtained from the study participants before beginning the study. This study was performed according to the principles of the Declaration of Helsinki. Eighteen hands of 10 patients were included in the study. Among them, eight were affected bilaterally, while two were affected unilaterally (one with CTS [2024 International Classification of Diseases, 10th Revision, Clinical Modification diagnostic code G56.00] in the right hand and one with CTS in the left hand). CTS was diagnosed by a single hand surgeon with more than 20 years' experience using the following criteria:⁹ ① paresthesia or dysesthesia with a weak and clumsy hand, which is exacerbated by repeated wrist use or falling asleep and relieved after postural adjustment or flicking of the hand;¹⁰ ② numbness due to sensory impairment in the territory innervated by the median nerve; ③ thenar muscle weakness and/or atrophy; and ④ positive Phalen's combined with Durkan's test¹¹ ± Tinel's sign. To perform the combination of Phalen's and Durkan's tests, the patient was asked to maximally flex their wrist while the examiner applied pressure at the level of the carpal tunnel. CTS was diagnosed if the patients fulfilled criteria ① and at least one of the remaining criteria. We excluded patients with cervical radiculopathy, nerve compressive disorders other than CTS, tendinitis, or osteoarthritis of the hand. In addition, 18 hands of 11 participants without CTS (non-CTS hands) were included in the study. Among them, seven had both hands evaluated and four had only one hand evaluated (three with evaluation of the right hand and one with evaluation of the left hand). The 18 non-CTS hands did not exhibit any musculoskeletal or neurological disorders. To confirm the absence of CTS in these hands, we assessed for sensory problems or motor weakness and confirmed the absence of any CTS-related symptom.

Collection of Data

Data on age; sex; hand dominance; presence of pain and paresthesia in the hand; nocturnal symptoms; and loss of power, dexterity, and endurance were collected by the same hand surgeon. In addition, physical examination, evaluation of carpometacarpal joint tenderness, and manual muscle testing of the APB were conducted.

Evaluation of the Presence of “Pronation Compensation Sign”

The single investigator (a hand surgeon with more than 20 years' experience) who was blinded to the presence of CTS evaluated the presence of “pronation compensation sign”. The test was conducted in the sitting position. Participants placed both their wrists and hands on the table in a supinated position, the second metacarpophalangeal joint in contact with the table (Figure 1, Video S1). The elbow is in a flexed position. The subjects were then asked to perform palmar abduction of the thumb. The instruction was given as follow:

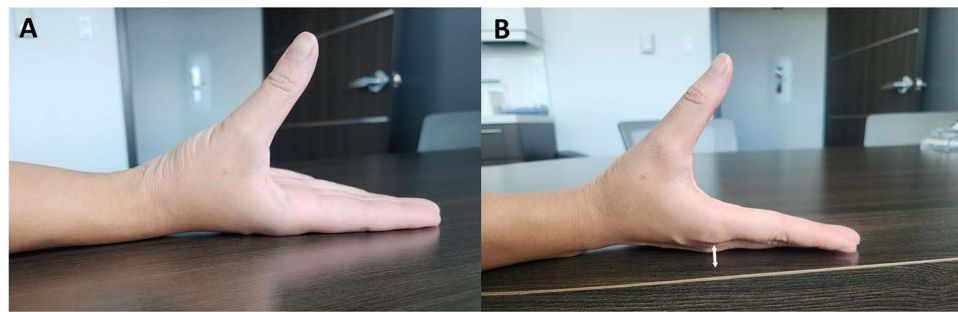


Figure 1 Findings of (A) negative “pronation compensation sign” as the second metacarpophalangeal joint remains in contact with the table while the thumb goes into palmar abduction. (B) positive “pronation compensation sign” as the forearm pronates to compensate for abductor pollicis brevis muscle weakness causing the second metacarpophalangeal joint to lift off the table (indicated by the arrow).

Bring your thumb up towards the ceiling while trying to keep this joint (surgeon pointing at the second metacarpophalangeal joint) in constant contact with the table.

When compensatory pronation movement of the wrist occurred and it caused the dorsal aspect of the second metacarpophalangeal joint to lose contact with the table surface, the “pronation compensation sign” was considered to be positive.

Data Analysis

Data were analyzed using the Statistical Package for the Social Sciences (SPSS) version 27.0 (IBM Corp., Armonk, NY). Summaries of the characteristic variables were obtained using descriptive analysis; quantitative and qualitative variables were represented as mean \pm standard deviation and frequencies (percentages), respectively. Demographic data and the presence of the “pronation compensation sign” were compared between CTS and non-CTS hands using the chi-square test and Mann–Whitney *U*-test. Statistical significance was set at $p < 0.05$. The sensitivity, specificity, positive predictive value (PPV), and negative predictive value (NPV) of the “pronation compensation sign” for CTS were calculated.

Results

The age and sex ratio were not significantly different between those with and without CTS (age: CTS hands = 52.5 ± 13.8 years, non-CTS hands = 43.2 ± 12.3 years, $p = 0.161$; sex ratio: CTS hands = 12:6, non-CTS hands = 9:9, $p = 0.310$). In addition, all included patients were right-handed. Of the 18 CTS hands, 15 (83.3%) had neuropathic pain. Additionally, all 18 CTS hands (100%) had paresthesia. Neuropathic pain or paresthesia was aggravated during sleep in 16 CTS hands (88.3%). Loss of power, dexterity, and endurance was observed in 15 (83.3%), 7 (38.9%), and 11 (61.1%) CTS hands, respectively. Thenar eminence atrophy was observed in 13 CTS hands (72.2%). The combination of Phalen’s and Durkan’s test and Tinel’s sign were positive in all 18 CTS hands (100%). Tenderness of the carpometacarpal joint was not observed in any of the 18 CTS hands (0%). On the MMT of the APB, all 18 CTS hands showed grade 3 or 4. In contrast, none of the non-CTS hands had neuropathic pain; paresthesia; nocturnal aggravation of symptoms; thenar eminence atrophy; or loss of power, dexterity, or endurance (0%). In addition, all 18 non-CTS hands were negative for both Phalen’s test and Tinel’s sign (0%). Furthermore, tenderness of the carpometacarpal joint was absent, and the MMT result was grade 5 in all non-CTS hands.

All CTS hands were positive for the “pronation compensation sign”. Additionally, all non-CTS hands were negative for the “pronation compensation sign” (Table 1). All 18 hands that were positive for the “pronation compensation sign” were CTS hands, and all 18 hands that were negative for the “pronation compensation sign” were non-CTS hands. Therefore, the

Table 1 Classification of the Included Hands Based on the Presence of the “Pronation Compensation Sign”

	Pronation Compensation Sign +	Pronation Compensation Sign -
Carpal tunnel syndrome +	18	0
Carpal tunnel syndrome -	0	18

sensitivity and specificity of the “pronation compensation sign” for diagnosing CTS were both 100%. Furthermore, the PPV and NPV of the “pronation compensation sign” for CTS were both 1.000. The rates of presence of the “pronation compensation sign” were significantly different between CTS and non-CTS hands ($p < 0.001$).

Discussion

In the current study, we describe a test called “pronation compensation sign” to help clinicians diagnose CTS more easily and accurately. Based on our results, the sensitivity, specificity, PPV, and NPV of the “pronation compensation sign” were excellent.

To diagnose CTS through physical examination, clinicians should conduct various tests and integrate their results to determine the presence of CTS. However, the accuracy of physical examination has not been extensively studied.^{12–14} In 1997, Kuhlman et al evaluated the sensitivity of each physical sign of carpal tunnel syndrome.¹³ Hypoesthesia in the area innervated by the median nerve and Phalen’s test had sensitivities of 51%. The sensitivity of Tinel’s sign was 23%. They reported that APB weakness was the most sensitive sign (66%) for diagnosing CTS. Furthermore, APB weakness has been reported in up to 94% of patients with CTS.^{12,14} Based on the results of previous studies,^{12–14} we aimed to suggest a test for APB weakness. The results of manual muscle testing vary depending on the examiner, and accurate measurement of APB weakness is challenging unless performed by specialists in neuromuscular disorders. Thus, we proposed an indirect test (ie, the “pronation compensation sign”) to identify APB weakness without relying on manual muscle testing.

Palmar abduction of the thumb is the primary action of the APB muscle.¹⁵ When APB weakness caused by CTS makes palmar abduction of the thumb difficult, patients tend to compensate by pronating their wrists and hands to raise their thumbs toward the ceiling. When this compensatory movement is exhibited by a patient with CTS, it is referred to as a positive “pronation compensation sign”. Although the diagnostic value of this sign was investigated in a limited number of CTS and non-CTS hands, all CTS hands showed a positive sign, and all non-CTS hands showed a negative sign. Therefore, we believe that the “pronation compensation sign” has an excellent diagnostic value. If a patient exhibits a positive “pronation compensation sign”, clinicians may strongly consider the likelihood of CTS. Conversely, clinicians may consider CTS less likely if a patient shows a negative sign.

In our study, we found that the “pronation compensation sign” could help clinicians in diagnosing CTS more easily and accurately. It has excellent diagnostic accuracy in evaluating CTS. The “pronation compensation sign” is a visual sign demonstrating APB weakness that is newly described here. We believe that its use in addition to Tinel’s sign, Durkan’s test, and Phalen’s test will help clinicians diagnose CTS with high diagnostic accuracy. The “pronation compensation sign” will contribute to appropriate and timely treatment of CTS, possibly preventing long-term complications. However, our study is limited in that it was a preliminary study, including only a small number of CTS and non-CTS hands and omitted a calculation of the appropriate sample size. To be effectively utilized in clinical practice, investigating the diagnostic accuracy of the “pronation compensation sign” in a large number of patients with CTS and normal participants is necessary. Furthermore, the study was conducted in a single local clinic setting. Because our clinic is a private pay for service institution, in a country where universal healthcare is available, we believe that many patients included in this study might have had an advanced stage of CTS, compared to a general population of carpal tunnel patients which could have potentially inflated the sensitivity and specificity of the test.

Funding

This work was supported by the National Research Foundation of Korea (NRF) grant funded by the Korea government (MSIT) (No. IRIS RS-2023-00219725).

Disclosure

The authors have no conflicts of interest to declare in this work.

References

1. Genova A, Dix O, Saefan A, Thakur M, Hassan A. Carpal tunnel syndrome: a review of literature. *Cureus*. 2020;12(3):e7333. doi:10.7759/cureus.7333

2. Chammas M, Boretto J, Burmann LM, Ramos RM, Santos Neto FC D, Silva JB. Carpal tunnel syndrome - Part I (anatomy, physiology, etiology and diagnosis). *Rev Bras Ortop.* 2014;49(5):429–436. doi:10.1016/j.rbo.2013.08.007
3. Joshi A, Patel K, Mohamed A, et al. Carpal Tunnel syndrome: pathophysiology and comprehensive guidelines for clinical evaluation and treatment. *Cureus.* 2022;14(7):e27053. doi:10.7759/cureus.27053
4. Taylor-Gjevne RM, Gjevne JA, Nair B. Suspected carpal tunnel syndrome: do nerve conduction study results and symptoms match? *Can Fam Physician.* 2010;56(7):e250–254.
5. Areson DG, Filer WG, Harris MG, Jf H Jr, Shuping LT, Traub R. Accuracy of the scratch collapse test for carpal tunnel syndrome in comparison with electrodiagnostic studies. *Hand.* 2022;17(4):630–634. doi:10.1177/1558944719895786
6. Sibbald M, Cavalcanti RB. The biasing effect of clinical history on physical examination diagnostic accuracy. *Med Educ.* 2011;45(8):827–834. doi:10.1111/j.1365-2923.2011.03997.x
7. Neral M, Imbriglia JE, Carlson L, Wollstein R. Motor Examination in the diagnosis of carpal tunnel syndrome. *J Hand Microsurg.* 2017;9(02):67–73. doi:10.1055/s-0037-1603346
8. Picasso R, Zaottini F, Pistoia F, et al. Ultrasound of the palmar aspect of the hand: normal anatomy and clinical applications of intrinsic muscles imaging. *J Ultrason.* 2023;23(94):e122–e130. doi:10.15557/JoU.2023.0021
9. Lee SH, Choi HH, Chang MC. Effect of ultrasound-guided partial release of the transverse carpal ligament with a needle in patients with refractory carpal tunnel syndrome. *Pain Physician.* 2022;25(1):E141–145.
10. Hansen PA, Micklesen P, Robinson LR. Clinical utility of the flick maneuver in diagnosing carpal tunnel syndrome. *Am J Phys Med Rehabil.* 2004;83(5):363–367. doi:10.1097/01.PHM.0000124439.14757.99
11. Wiesman IM, Novak CB, Mackinnon SE, Winograd JM. Sensitivity and specificity of clinical testing for carpal tunnel syndrome. *Can J Plast Surg.* 2003;11(2):70–72. doi:10.1177/229255030301100205
12. Geere J, Chester R, Kale S, Jerosch-Herold C. Power grip, pinch grip, manual muscle testing or thenar atrophy - which should be assessed as a motor outcome after carpal tunnel decompression? A systematic review. *BMC Musculoskelet Disord.* 2007;8(1):114. doi:10.1186/1471-2474-8-114
13. Kuhlman KA, Hennessey WJ. Sensitivity and specificity of carpal tunnel syndrome signs. *Am J Phys Med Rehabil.* 1997;76(6):451–457. doi:10.1097/00002060-199711000-00004
14. Rozmaryn LM, Bartko JJ, Isler ML. The Ab-Adductometer: a new device for measuring the muscle strength and function of the thumb. *J Hand Ther.* 2007;20(4):311–324. (). doi:10.1197/j.jht.2007.07.010
15. Skoff HD. The role of the abductor pollicis brevis in opposition. *Am J Orthop.* 1998;27(5):369–370.

Journal of Pain Research

Dovepress

Publish your work in this journal

The Journal of Pain Research is an international, peer reviewed, open access, online journal that welcomes laboratory and clinical findings in the fields of pain research and the prevention and management of pain. Original research, reviews, symposium reports, hypothesis formation and commentaries are all considered for publication. The manuscript management system is completely online and includes a very quick and fair peer-review system, which is all easy to use. Visit <http://www.dovepress.com/testimonials.php> to read real quotes from published authors.

Submit your manuscript here: <https://www.dovepress.com/journal-of-pain-research-journal>